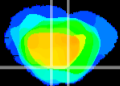
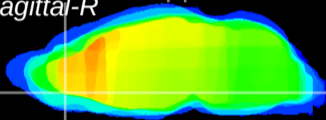


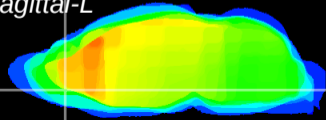
Coronal



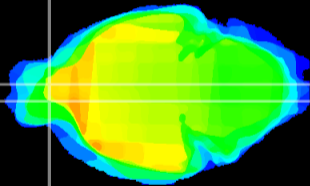
Sagittal-R



Sagittal-L



ViBrism: CX02802  
Horizontal



OB posterior